

Gray-level hit-or-miss transform based region-growing for automatic segmentation of 3D coronary arteries

BESSEM BOURAOUI^{1,2}, CHRISTIAN RONSE¹,
JOSEPH BARUTHIO², NICOLAS PASSAT¹ and
PHILIPPE GERMAIN³

¹ *Laboratoire des Sciences de l'Image, de l'Informatique et de la Télé-détection (LSIT), UMR 7005 CNRS/ULP, France.*
`{bouraoui,ronse,passat}@lsiit.u-strasbg.fr`

² *Laboratoire d'Imagerie et de Neurosciences Cognitives (LINC), UMR 7191 CNRS/ULP, France.*
`baruthio@ipb.u-strasbg.fr`

³ *Service de Radiologie, Hôpitaux Universitaires de Strasbourg.*
`phil.germain@free.fr`

1. Introduction

In this paper we propose a fully automatic algorithm for coronary artery extraction from X-ray data (3D-CT scan, 64 detectors). Growing and thresholding methods, in their most general form, are not sufficient to extract only the whole coronary arteries, because of the properties of these images [1]. Finding appropriate methods is known to be a challenging problem because of the data imperfections such as noise, heterogeneous intensity and contrasts of similar tissues. We deal with these challenges by employing discrete geometric tools to fit on the arteries form independently from any perturbation of the data.

2. Background

Region-growing Basically, region-growing methods are based on two main concepts: seed-point(s) and expansion criterion. Starting from the seed-point(s), and exploring the currently segmented object neighborhood, if the expansion criterion is satisfied for a given point, this point is added to the object. With the data we are interested in, it can be assumed that vessels are brighter than the surrounding tissues, but a simple thresholding is not sufficient to define an expansion criterion. To reach our objective two requirements are then essential [2]:

- no user seed-point selection but an automatically detected one;
- an expansion criterion independent of the variation of image properties.

Gray level hit-or-miss transform The hit-or-miss (HMT) in binary images is a classic mathematical morphology operator [3], that uses two structuring elements A and B . The operation is made

by testing two conditions: A has to belong to the object, while B has to belong to the background. This binary operator is not easily extended to gray level images. We use a definition of HMT operator [4] that assigns to A and B gray-levels a and b , respectively. Following this definition, the gray-level (GL) HMT compares the minimum intensity a_{min} in A to the maximum intensity b_{max} in B : if $a_{min} > (b_{max} + a - b)$, then the point is selected by the GL HMT.

3. Images and coronary artery anatomy

The considered images do not cover only the heart, but a large part of the trunk, including the lungs, the spinal column, the liver and a part of the stomach (Fig. 1(a)). With 512^3 as dimension, a reduction of the search space becomes necessary. There are two main coronary arteries (the left one and the right one): both of them originate from the beginning of the aorta, immediately above the aortic valve. The aorta is the largest single blood vessel in the body, corresponding to a large tubular structure whose axial section is circular at almost 3 cm from the aortic valve and presenting a wall sufficiently thick to be visualized in the data.

4. Segmentation method

Heart-zone automatic detection Using a GL HMT, the detection of the heart zone is realized with two *ad hoc* structuring elements: a sphere for A , and for B one of two spheres whose centers are horizontally symmetrical w.r.t. the center of A (Fig. 1(b)). The lungs correspond to the background which has to be fit by B , while the heart corresponds to the object which has to be fit by A . As result, only the heart zone is kept, realizing an important reduction of the search area (Fig. 1(c)).

Aorta automatic detection About 2 to 3 cm above the aortic valve, an axial section of the aorta presents a circular shape, with a radius varying from 2 cm to 4 cm, this value depending on the patient and the conditions of the image acquisition. Our goal is to localize this circular shape using a GL HMT with multi-sized structuring elements. A horizontal disk (A) with a variable radius models the

object. It is surrounded by one background point on every quarter (B) (Fig. 2(a)). The center of the detected circular shape will be used as seed for a first region-growing, the expansion criterion of which will involve two parameters: intensity and texture [5]. This region-growing will be stopped by the aorta wall on the sides and by the aortic valve down (Fig. 2(a)).

Coronary arteries seed point detection The coronary arteries are the only tubular structures that generate from the aorta. The idea is to search this tubular form in the wall of the aorta. Following a strategy close to the one proposed in [6], a GL HMT is applied, with a sphere as object and 4 points surrounding this sphere as background. These points belong to the plane normal to the artery axis. The choice of these points defines the axis direction of the searched coronary artery. 13 structuring elements, corresponding to the 13 discrete principal directions are then used (Fig. 2(b)).

Coronary arteries detection Starting from the two seed-points previously detected on the aorta wall, a region-growing is performed, applying the GL HMT on every neighbor as criterion. The involved structuring elements are the same as those described in the previous subsection. The obtained result is illustrated in Fig. 2(b).

5. Discussion and conclusion

We have proposed a fully automatic segmentation method for the coronary arteries. The method was tested on 4 coro-scan images, visually providing satisfactory results. Validation work on 40 other patients is currently in progress. Some improvements are in progress. As mentioned above, images have a rather considerable size, which makes the cost in computing time prohibitive, particularly during the heart zone detection and the segmentation of the aorta (Table 1). A multi-resolution approach has then been integrated. On the first two steps, an under-sampling to 64^3 size image is carried out. Once the aorta is detected, an over-sampling enables to get back the original size. This approach enables the application of the algorithm with a lower complexity.

Table 1. Effects of the sampling on different detection.

Object / Volume	512^3	64^3
Heart zone	45 mn	5 mn
Aorta	10 mn	1 mn
Coronary arteries	1 mn	-

6. Final algorithm

Input: Original image 512^3 (Fig. 1(a)).

-Under-sampling to get a 64^3 image.

-Heart zone detection by GL HMT application (Fig. 1(c)).

-Aorta segmentation.

-Circular section aorta detection: center used as seed point.

-Region-growing with intensity and texture as criterion (Fig. 2(a)).

-Over-sampling of the aorta to a 512^3 image.

-Search of the two coronary arteries seed points on the aorta wall, using GL HMT.

-Coronary arteries detection with a region-growing using GL HMT as criterion.

Output: Coronary arteries 512^3 image (Fig. 2(b)).

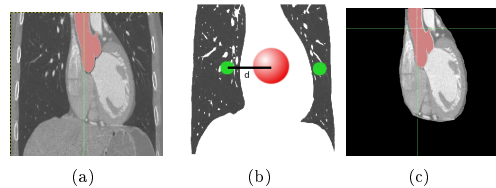


Figure 1. Heart zone detection

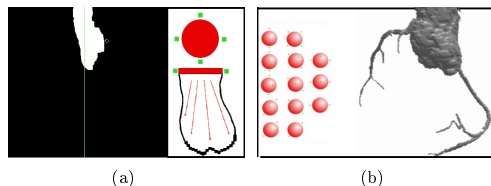


Figure 2. Aorta detection and coronary arteries segmentation.

References

- [1] C. Lorenz, S. Renisch, T. Schlatholter, and T. Bulow, *Simultaneous segmentation and tree reconstruction of the coronary arteries in MSCT images*, SPIE Medical Imaging: Physiology and Function: Methods, Systems, and Applications 2003, Proceedings, Vol. 5031, San Diego, CA, USA, 2003, pp. 138–148.
- [2] N. Passat, C. Ronse, J. Baruthio, J.-P. Armspach, C. Mailhot, and C. Jahn, *Region-growing segmentation of brain vessels: An atlas-based automatic approach*, Journal of Magnetic Resonance Imaging **21** (2005), no. 6, 715–725.
- [3] P. Soille, *Morphological Image Analysis: Principles and Applications*, 2nd, Springer-Verlag, Heidelberg, 2003.
- [4] B. Naegel, N. Passat, and C. Ronse, *Grey-level hit-or-miss transforms - Part II: Application to angiographic image processing*, Pattern Recognition **40** (2007), no. 2, 648–658.
- [5] J. Flureau, *Multi-object segmentation of cardiac MSCT data using SVM classifiers and connectivity algorithm*, Computers in Cardiology 2006, Proceedings, Vol. 33, Valencia, Spain, 2006.
- [6] B. Naegel, C. Ronse, and L. Soler, *Segmentation automatique de l'entrée de la veine porte dans le foie par application de la transformée en tout-ou-rien en niveaux de gris*, ORASIS 2003, Proceedings, Gérardmer, France, 2003.